

Fat Embolism after Surgery for Gynecomastia

Jinekomasti Cerrahisinden Sonra Yağ Embolisi

Maria Grozeva¹, Radoswet Gornev², Vania Mitova², Rossen Hadjiev¹, Miroslav Zashev², Dimitur Penchev²

¹Forensic Medicine Department, Lozenetz Hospital, Sofia, Bulgaria

²General Surgery Department, Lozenetz Hospital, Sofia, Bulgaria

Abstract

Gynecomastia is a benign enlargement of the male breast, secondary to gland proliferation and is a common problem among the male population. Treatment is primarily surgical. The most common intra- and postoperative complication is bleeding, followed by seroma, infection, insufficient results, inverted nipple and nipple necrosis. The embolism is one of the non-specific complications. A 24-year-old male was presented to the Surgery Department with a diagnosis unilateral gynecomastia. The operation proceeded without complication and around 10 hours later, the patient complained of weakness in all four limbs, later nausea, and vomiting and after full cardiopulmonary resuscitation, the patient died. The main reason for the patient's death was concluded to be a postoperative pulmonary thromboembolism and fat embolism was discovered. In addition, there was a papillary carcinoma of the thyroid, which was missed before. We reported that unilateral gynecomastia associated with papillary carcinoma of the thyroid detected rarely at autopsy and fat embolism after surgery for gynecomastia is a rare complication.

Keywords: Gynecomastia, Fat embolism, Autopsy.

Özet

Jinekomasti, gland proliferasyonuna sekonder olarak gelişen benign erkek meme büyümesidir ve erkek popülasyonunda yaygın bir problemdir. Tedavisi öncelikle cerrahidir. En yaygın intra ve postoperatif komplikasyonu kanamadır, ardından seroma, enfeksiyon, yetersiz sonuçlar, ters meme ucu ve meme ucu nekrozu izler. Emboli non-spesik komplikasyonlarından biridir. 24 yaşındaki erkek hasta unilateral jinekomasti tanısıyla Cerrahi Departmanına başvurdu. Herhangi bir komplikasyon olmadan ameliyat tamamlandı. Yaklaşık 10 saat sonra 4 ekstremitede güçsüzlük, ardından bulantı ve kusma şikayetleri başladı ve tam bir kardiyopulmoner resüstasyonda sonra hasta öldü. Hastanın başlıca ölüm nedeni postoperatif pulmoner tromboembolizm olarak kabul edildi ve yağ embolisi tespit edildi. Ayrıca tanısı konulmayan troid papiller karsinoma vardı. Biz jinekomasti cerrahisi sonrası yağ embolisi komplikasyonu görülen ve otopside nadir görülen unilateral jinekomasti ile beraber troid papiller karsinom olgusunu raporladık.

Anahtar kelimeler: Jinekomasti, Yağ embolisi, Otopsi.

1. Introduction

Gynecomastia is a benign enlargement of the male breast, secondary to gland proliferation (1). It is a common problem among the male population with a reported prevalence of up to 36%. Various treatment techniques have been described, but none has gained universal acceptance (2). Treatment is primarily surgical. The most common complication is bleeding, followed by seroma, infection, insufficient results, inverted nipple and nipple necrosis (3). The embolism is one of the non-specific complications (4). We reported that unilateral gynecomastia associated with papillary carcinoma of the thyroid detected rarely at autopsy and fat embolism after surgery for gynecomastia is a rare complication.

2. Case Report

A 24-year-old male was presented to the One-Day Surgery Department with a diagnosis "Unilateral gynecomastia". After all standard examinations, he underwent surgery under

general anesthesia. During the operation a tumor fibrosis formation (50 mm) was found on the right breast. The following operations were performed: subcutaneous excision of the parenchyma and fat tissue and drainage. The excised tissue was sent for histological examination. The operation proceeded without complication. The patient recovered from anesthesia, and when alert, showed no signs of respiratory distress and was communicating comfortably. Around 10 hours later, the patient complained of weakness in all four limbs. He had nausea and vomiting. The patient was psychomotor aroused and slightly disorientated, with the arterial pressure 110/60 mm/Hg and pulse 100 per minute. A consultation with the neurologist and the anesthesiologist was implemented. The patient's neurological status was normal, without any pathological findings. The specialists concluded that it was a hysterical attack. Thirty minutes later, the upper half of the patient's body suddenly turned blue and he lost consciousness. There was no heartbeat and breathing. After full cardiopulmonary resuscitation, the patient died. The main reason for the patient's death was concluded to be a postoperative pulmonary thromboembolism at the autopsy.

Corresponding Author: Maria Grozeva
Forensic Medicine Department, Lozenetz Hospital, Sofia, Bulgaria
E-mail: mgrozevabg@yahoo.com

Geliş: 18.03.2015

Düzeltilme: 07.04.2015

Kabul: 30.04.2015

After the fat embolism was discovered. In addition, there was a papillary carcinoma of the thyroid, which was missed before. It was accepted the fat embolism was the reason for the patient's death.

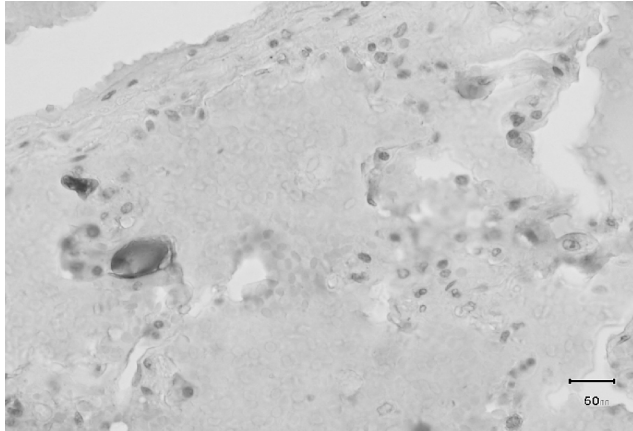


Fig 1. Fat embolism.

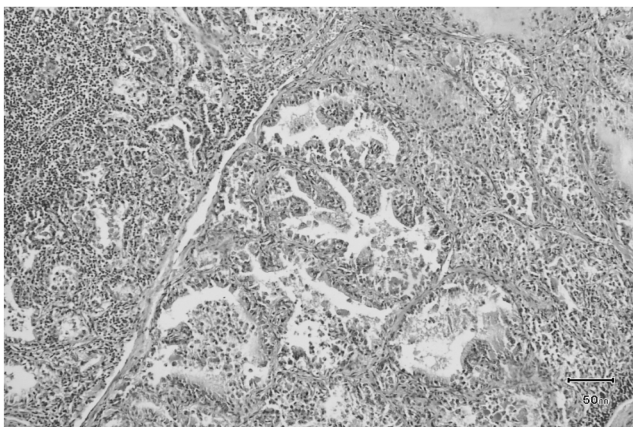


Fig 2. Papillary carcinoma of the thyroid.

3. Discussion

Gynecomastia is a relatively common disease. Subcutaneous mastectomy is performed on symptomatic patients and on those desiring cosmetic changes (1). The most common complication is bleeding, followed by seroma, infection, insufficient results, inverted nipple and nipple necrosis (3). The embolism is one of the non-specific complications. An explanation for the fat embolism could be the peculiarities of the breast's blood supply. The thoracic internal vein has perforative branches, which connect venous blood flows directly from the mummies into the lungs (4). Because of the patient's papillary carcinoma of the thyroid, it is possible that the patient had paraneoplastic syndrome. Typically, paraneoplastic syndromes are detected in patients after a cancer diagnosis. Paraneoplastic syndrome manifests itself clinically with concomitant tumours. It is usually in breast tumours, lungs, ovarian tumours, etc. The most common

manifestations of paraneoplastic syndrome are ectopic secretion of hormones and tendency to embolism. The development of these disorders does not necessarily correlate with a cancer stage or prognosis (5-6).

The main complications after breast surgery can be divided into two groups: some general, non-specific complications (wound infections, seroma formation, hematoma) and specific, breast-related procedures (7). Venous thromboembolism (VTE), which includes both deep venous thrombosis and pulmonary embolism, is an important cause of morbidity and mortality in patients with cancer (8). The estimated annual incidence of a first episode of VTE in the general population is 0.117% (9). Patients with cancer have a 4-fold increased risk of VTE, for an annual incidence of approximately 0.48% (10).

In a recent survey in the United Kingdom, of 126 surgeons performing breast surgery, 38 surgeons (30%) did not routinely administer thromboprophylaxis. The estimated incidence of VTE after breast surgery in that survey was less than 1% (11). The general risk factors for thromboembolic events in adults, identified frequently in literature as venostasis, hypercoagulability, vessel wall inflammation (Virchow's triad), recent surgery or trauma, and malignancy, can be applied to children as well. Other risk factors, such as obesity, smoking, oestrogen therapy, prolonged bed rest, inherited disorders of coagulation and previous pulmonary embolism, are also well-accepted in literature as known risk factors for thromboembolic complications. In addition, according to a small number of studies, hypogonadism, risperidone and testosterone injections also seem to be related with the incidence of deep venous thrombosis and pulmonary embolism (12-15). JR Piggott and co-authors reported a case of bilateral pulmonary emboli after bilateral mastectomy in a 15-year-old boy with gynecomastia and hypogonadism. Furthermore, regarding all risk factors described so far, they also reported that BMI greater than 35 kg/m² was the main risk factor for a thromboembolic event in patients undergoing body contouring procedures (16). The fat embolism syndrome was first described by Von Bergmann, who cared for a man with a broken femur and symptoms of the syndrome in 1873 (17-18). Fat embolism mainly seem to occur after long bone fracture or a large area of soft tissue injury with the majority of cases being fat embolism of lung and occasional cases being combined embolisms of lung and brain as well. The onset of symptoms appears shortly after the injury or surgery. Lipid droplets can be observed within small pulmonary vessels and verified by special staining (19).

Fat embolism syndrome is an often-overlooked cause of breathlessness. The clinical background, chronology of symptoms and corroborative laboratory findings are

instrumental in a diagnosis of fat embolism syndrome. Management is mainly prevention of fat embolism syndrome, and organ supportive care (20).

Unilateral gynecomastia associated with papillary carcinoma of the thyroid is a rare case. On one hand, the main reason for gynecomastia might be an abnormal hormonal secretion. On the other hand, the paraneoplastic syndrome might be a reason for fat embolism. Fat embolism after surgery for gynecomastia is a rare complication. The data, however, is limited and based on case reports. That's why the patient's complaints are usually overlooked and the right diagnosis is missed.

References

1. Steele SR, Martin MJ, Place RJ., Gynecomastia: complications of the subcutaneous mastectomy, *Am Surg.* 2002;68(2):210-3.
2. Arvind A, Khan MA, Srinivasan K, Roberts J. Gynaecomastia correction: A review of our experience, *Indian J Plast Surg.* 2014;47(1):56-60.
3. Lapid O, Klinkenbijn JH, Oomen MW, van Wingerden JJ, Gynaecomastia surgery in the Netherlands: what, why, who, where....., *J Plast Reconstr Aesthet Surg.* 2014;67(5):702-6.
4. John E. Skandalakis, Gene L. Colborn, Thomas A. Weidman, Roger S. Foster, Jr., Andrew N. Kingsnorth, Lee J. Skandalakis, Panajiotis N. Skandalakis, Petros S. Mirilas, Skandalakis' Surgical Anatomy, Chapter 03
5. Lorraine C. Pelosof, MD, PhD and David E. Gerber, MD, Paraneoplastic Syndromes: An Approach to Diagnosis and Treatment, *Mayo Clin Proc.* 2010; 85(9): 838–854.
6. Spinazze S, Schrijvers D. Metabolic emergencies. *Crit Rev Oncol Hematol.* 2006;58:79-89.
7. Angeliq F. Vitug, MD, Lisa A. Newman, MD, MPH, FACS*, Complications in Breast Surgery, *Surg Clin N Am* 87 (2007) 431–451, University of Michigan, Breast Care Center, 1500 East Medical Center Drive., 3308 CGC, Ann Arbor, MI 48167, USA
8. Rickles FR, Edwards RL. Activation of blood coagulation in cancer: Trousseau's syndrome revisited. *Blood.* 1983;62:14–31.
9. Silverstein MD, Heit JA, Mohr DN, et al. Trends in the incidence of deep venous thrombosis and pulmonary embolism: a 25-year population-based study. *Arch Intern Med.* 1998;158:585–593.
10. Heit JA, Silverstein MD, Mohr DN, et al. Risk factors for deep vein thrombosis and pulmonary embolism: a population-based case-control study. *Arch Intern Med.* 2000;160:809–815.
11. Robert H. I. Andtbacka, MDCM, FRCSC, Gildy Babiera, MD, S.Eva Singletary, MD, Kelly K. Hunt, MD, FACS, Funda Meric-Bernstam, MD, FACS, Barry W. Feig, MD, FACS, Frederick C. Ames, MD, FACS, Merrick I. Ross, MD, FACS, Yvette Dejesus, MSN, and Henry M. Kuerer, MD, PhD, FACS; Incidence and Prevention of Venous Thromboembolism in Patients Undergoing Breast Cancer Surgery and Treated According to Clinical Pathways, *Ann Surg.* 2006; 243(1): 96–101.
12. Ramzi DW, Leeper KV. DVT and pulmonary embolism: Part 1. Diagnosis. *Am Fam Phys.* 2004;69:12.
13. Hafez DA, Kenkel JM, Nguyen MQ, et al. Thromboembolic risk assessment and the efficacy of enoxaparin prophylaxis in excisional body contouring surgery. *Plast Reconstr Surg.* 2008;122:269–79.
14. Bennet A, Sie P, Caron P, et al. Plasma fibrinolytic activity in a group of hypogonadic men. *Scand J Clin Lab Invest.* 1987;1:23–7.
15. Kamijo Y, Soma K, Nagai T, Kurihara K, Ohwada T. Acute massive pulmonary thromboembolism associated with risperidone and conventional phenothiazines. *Circ J.* 2003;1:46–8.
16. Piggott JR, Yazdani A. Bilateral pulmonary emboli after bilateral mastectomy in a 15 year-old boy with hypogonadism: A case report. *Can J Plast Surg.* 2010;18(4):e50-2.
17. James L. Glazer, MD, and Daniel K. Onion, MD, MPH, Fat Embolism Syndrome in a Surgical Patient, *BRIEF REPORTS, JABFP* 2001 Vol. 14 No. 4 (310-313)
18. Von Bergmann E. Ein fall todlicher fettembolie. *Berl klin Wochenscher* 1873;10:385.
19. Zhou L, Mu J, Dong HM, Zhang J., Forensic analysis of death caused by fat embolism: A study of 20 autopsy cases, *Fa Yi Xue Za Zhi.* 2013;29(6):431-3.
20. George J, George R, Dixit R, Gupta RC, Gupta N., Fat embolism syndrome, *Lung India.* 2013;30(1):47-53.